Wrist Fractures

ANDREW IRWIN,FRCS ED (ORTH)
CONSULTANT ORTHOPAEDIC SURGEON
WEST HERTS NHS TRUST, UK

Motec Life-UK

St Albans Abbey, 1077 onwards



Watford General Hospital

Gender Incidence of all Fractures 1988-98 in UK

JBJS Dec 2001, van Staa et al, 2001

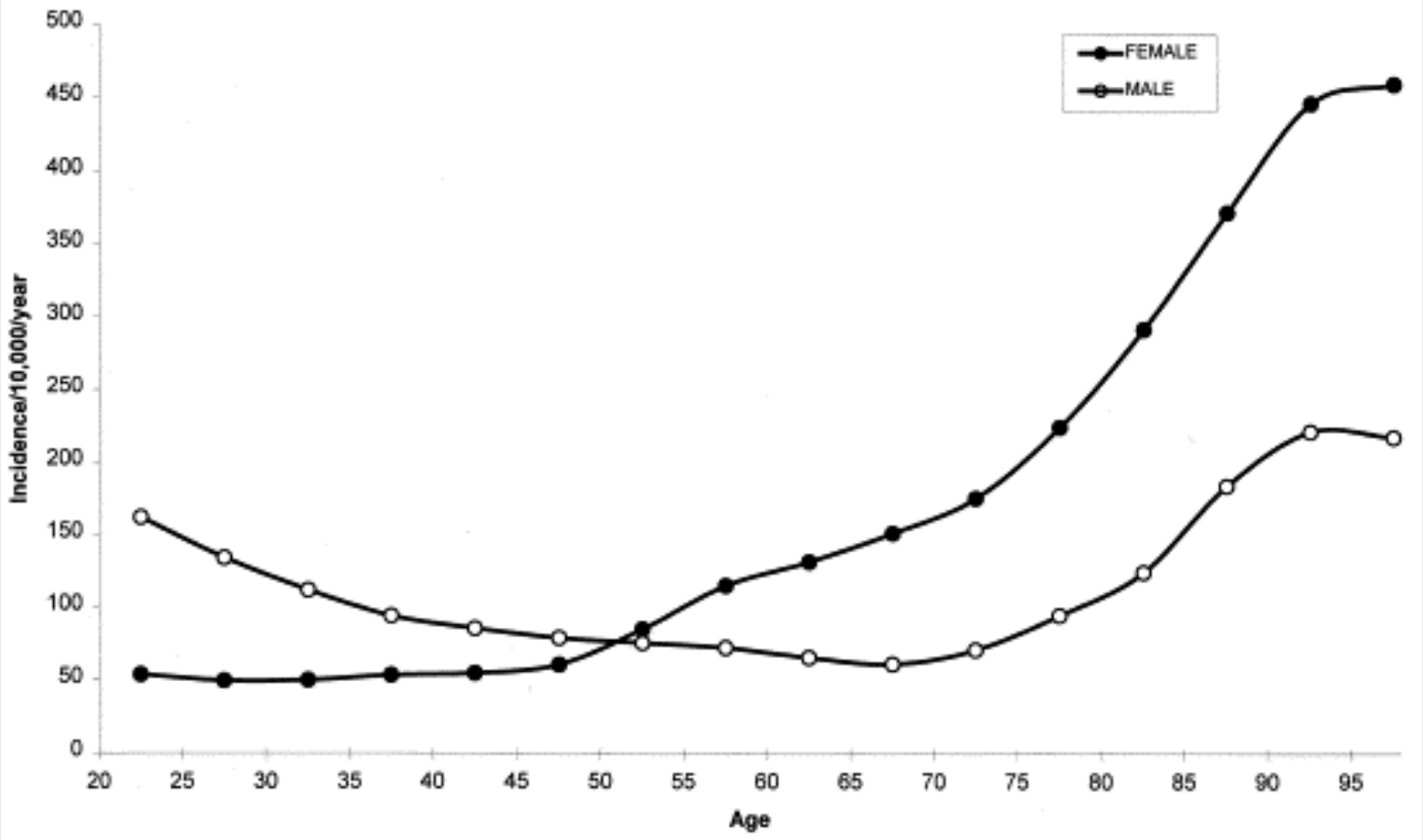

Incidence of wrist fractures

- Adult/elderly women more likely than men in the same age group to break a wrist seriously enough to require an operation. Rate of # climbs dramatically from age of 40.
- In 50s, women 3x more likely than men to suffer complex wrist bone #
- In their 60s, women are 5x as likely to suffer these kinds of # as men
- In their 70s broken wrist statistics are 10-1, in women's disfavour (Science Nordic, April 2013)
- Wrist fractures "result in clinically important functional decline in older women who are healthy and physically fit" (BMJ 2010)

Incidence of wrist v. other fractures

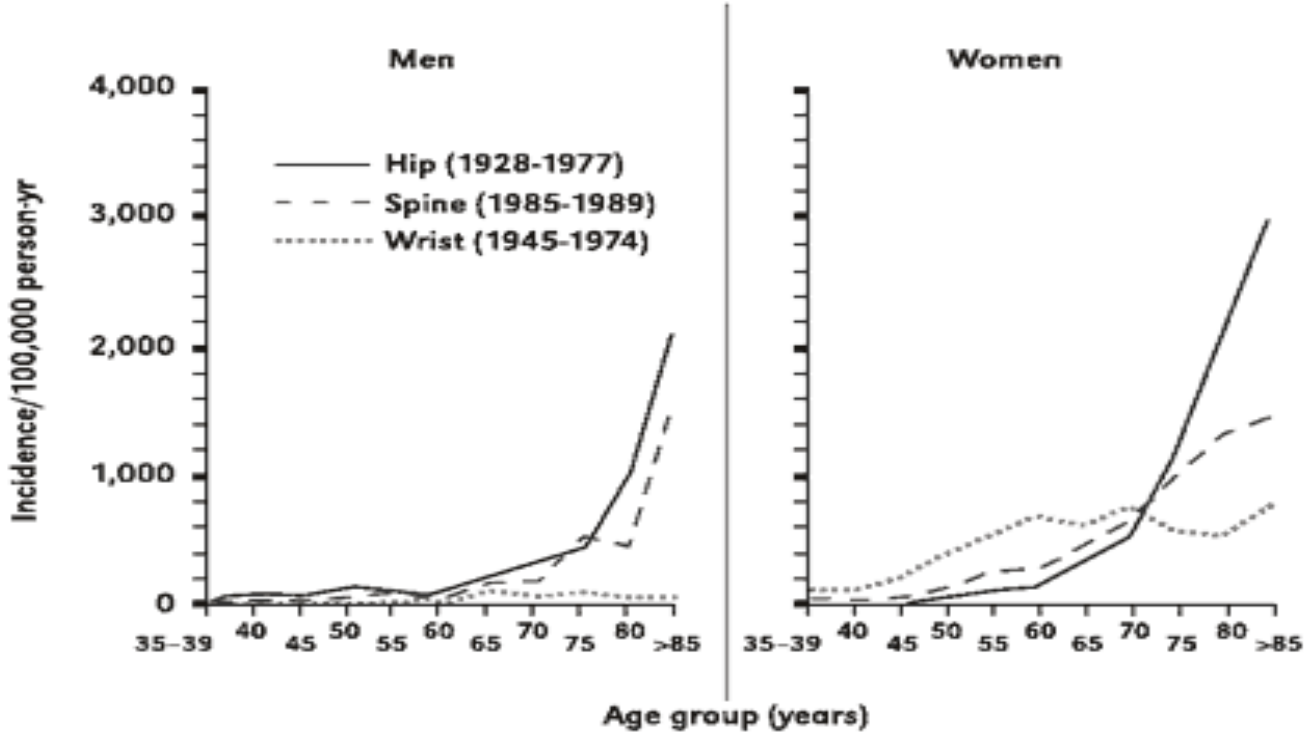

Figure 4–1. Age Specific Incidence Rates for Proximal Femur (Hip), Vertebral (Spine), and Distal Forearm (Wrist) Fractures in Rochester, Minnesota, Men and Women

Source: Cooper and Melton 1992.

Causes of Wrist Fracture

- History of wrist fracture includes the following:
  - Fall onto an outstretched hand
  - Direct trauma
  - Osteoporosis a factor

Examination

- Uninjured extremity for comparison
- Site of injury look for echymosis or swelling
- # of distal radius have characteristic deformities.
- Break in the skin indicating an open fracture
- Palpation with localisation at point of maximum tenderness defines injury

Abraham Colles, 1773-1843

- Professor of Anatomy, Surgery and Physiology at the Royal College of Surgeons in Ireland
- Treatise 1811, paper 1814 “On the Fracture of the Carpal Extremity of the Radius”

Colles Fracture

Colles' Fracture

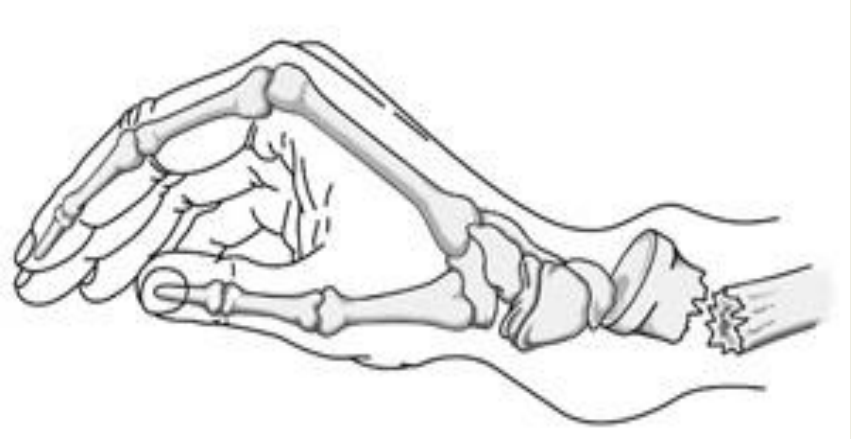

- Other ways the distal radius can break include:
- **Intra-articular fracture** extends into the wrist joint
- **Extra-articular fracture** that does not extend into the joint
- **Open fracture**
- **Comminuted fracture** when a bone is broken into more than two pieces

Robert William Smith, 1807-1873

- Like Colles, a graduate of Trinity College, Dublin
- 1847, corrected Colles in his book on fractures
- Chair of Surgery, Trinity College

Smith's Fracture

John Rhea Barton, 1794-1871

- John Rhea Barton, born Philadelphia, Pennsylvania;
- Pennsylvania Hospital as surgeon in 1823;
- said to be ambidextrous and did not move around once positioned for an operation;
- Known for Barton bandage, a figure-of-eight bandage to support the jaw, and Barton forceps, curved obstetric forceps.

Barton's Fracture

Figure 179 John Rhea Barton (1794–1871)

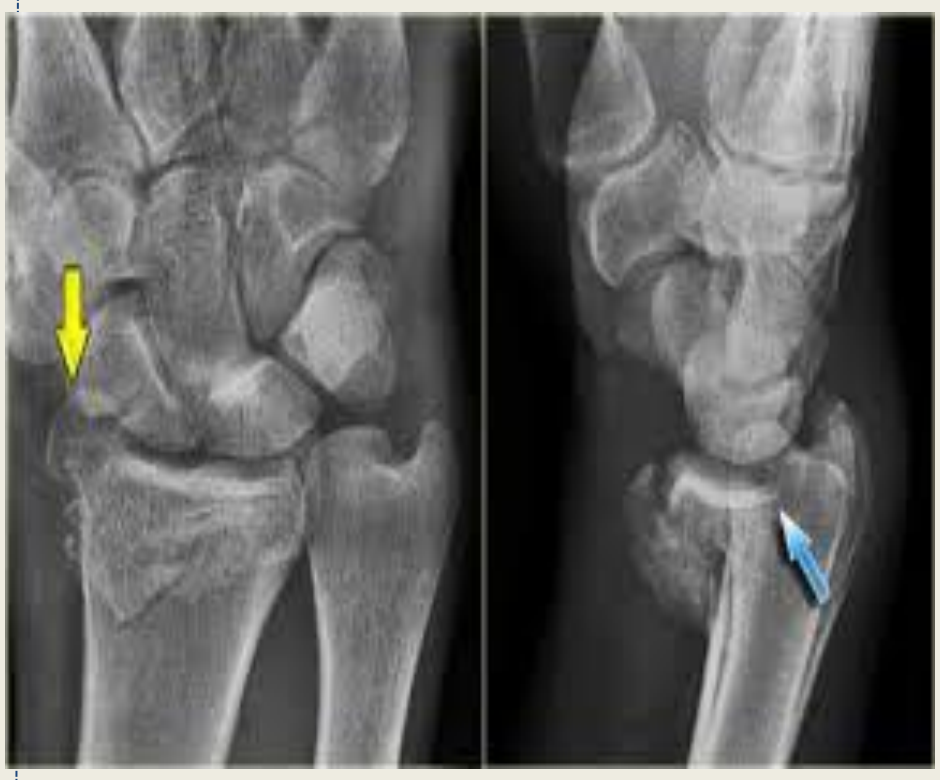

Comparison of fractures

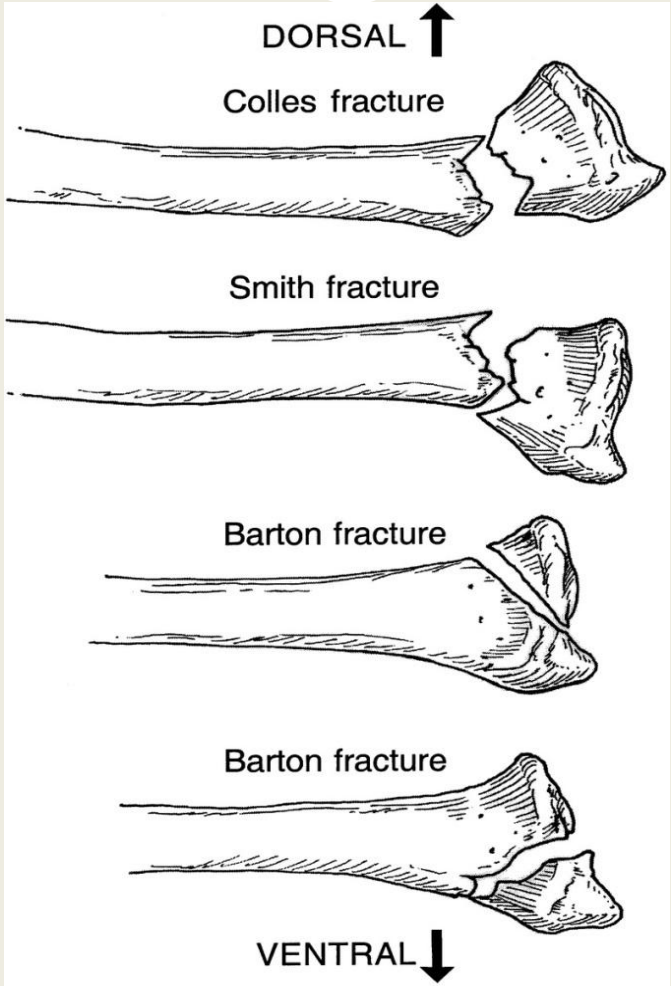

JF Sarwark, ed: Essentials of Musculoskeletal Care, American Academy of Orthopaedic Surgeons, 2010

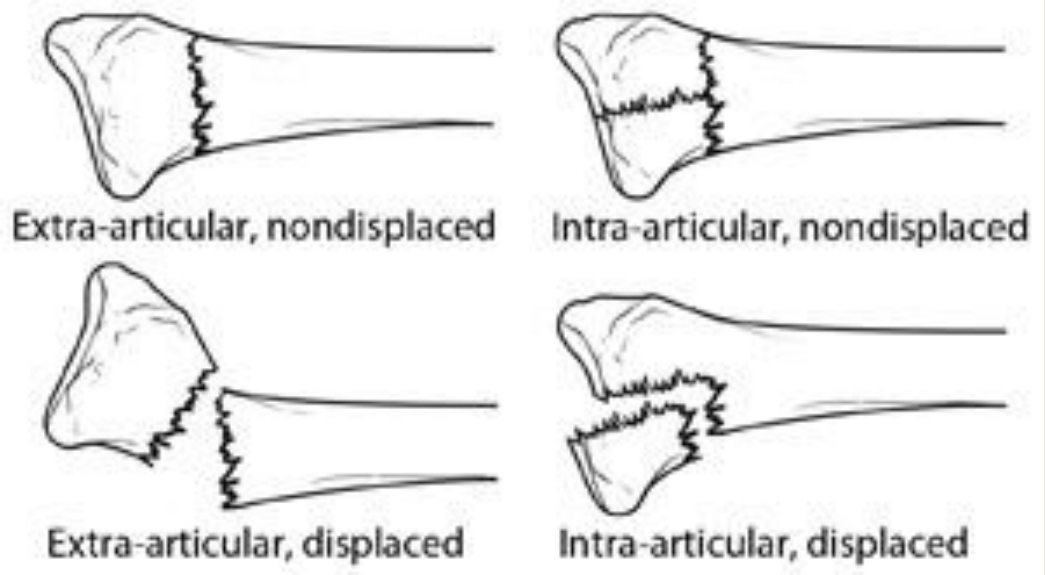

AO Classification of Wrist

2 Radius/ulna

21 proximal

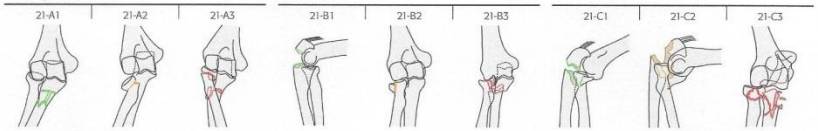

21-A extraarticular fracture
21-A1 ulna fractured, radius intact
21-A2 radius fractured, ulna intact
21-A3 both bones

21-B articular fracture
21-B1 ulna fractured, radius intact
21-B2 radius fractured, ulna intact
21-B3 one bone articular fracture, other extraarticular

21-C articular fracture of both bones
21-C1 simple
21-C2 one artic. simple, other artic. multifragmentary
21-C3 multifragmentary

22 diaphyseal

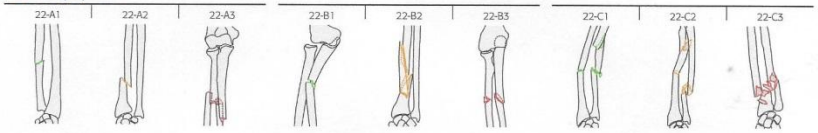

22-A simple fracture
22-A1 ulna fractured, radius intact
22-A2 radius fractured, ulna intact
22-A3 both bones

22-B wedge fracture
22-B1 ulna fractured, radius intact
22-B2 radius fractured, ulna intact
22-B3 one bone wedge, other simple or wedge

22-C complex fracture
22-C1 ulna complex, radius simple
22-C2 radius complex, ulna simple
22-C3 both bones complex

23 distal

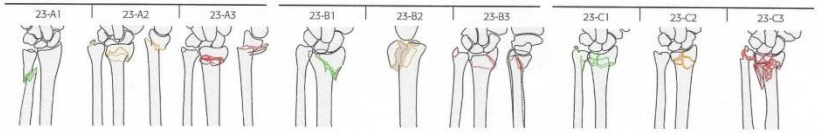

23-A extraarticular fracture
23-A1 ulna fractured, radius intact
23-A2 radius, simple and impacted
23-A3 radius, multifragmentary

23-B partial articular fracture of radius
23-B1 sagittal
23-B2 coronal, dorsal rim
23-B3 coronal, palmar rim

23-C complete articular fracture of radius
23-C1 articular simple, metaphyseal simple
23-C2 articular simple, metaphyseal multifragmentary
23-C3 articular multifragmentary

Treatment

- Conservative – MUA and POP
- Operative
- - minimally invasive, percutaneous wires
- threaded or unthreaded wires Kapandji wires
- ORIF

AO Principles of Internal Fixation

- **In 1958, AO formulated 4 basic principles of fracture fixation:**
  - **Anatomic reduction**
  - **Stable fixation**
  - **Preservation of blood supply**
  - **Early, active mobilisation**

Kapandji wires, AO

a Percutaneous K-wires for extraarticular # and b Intrafocal percutaneous K-wires

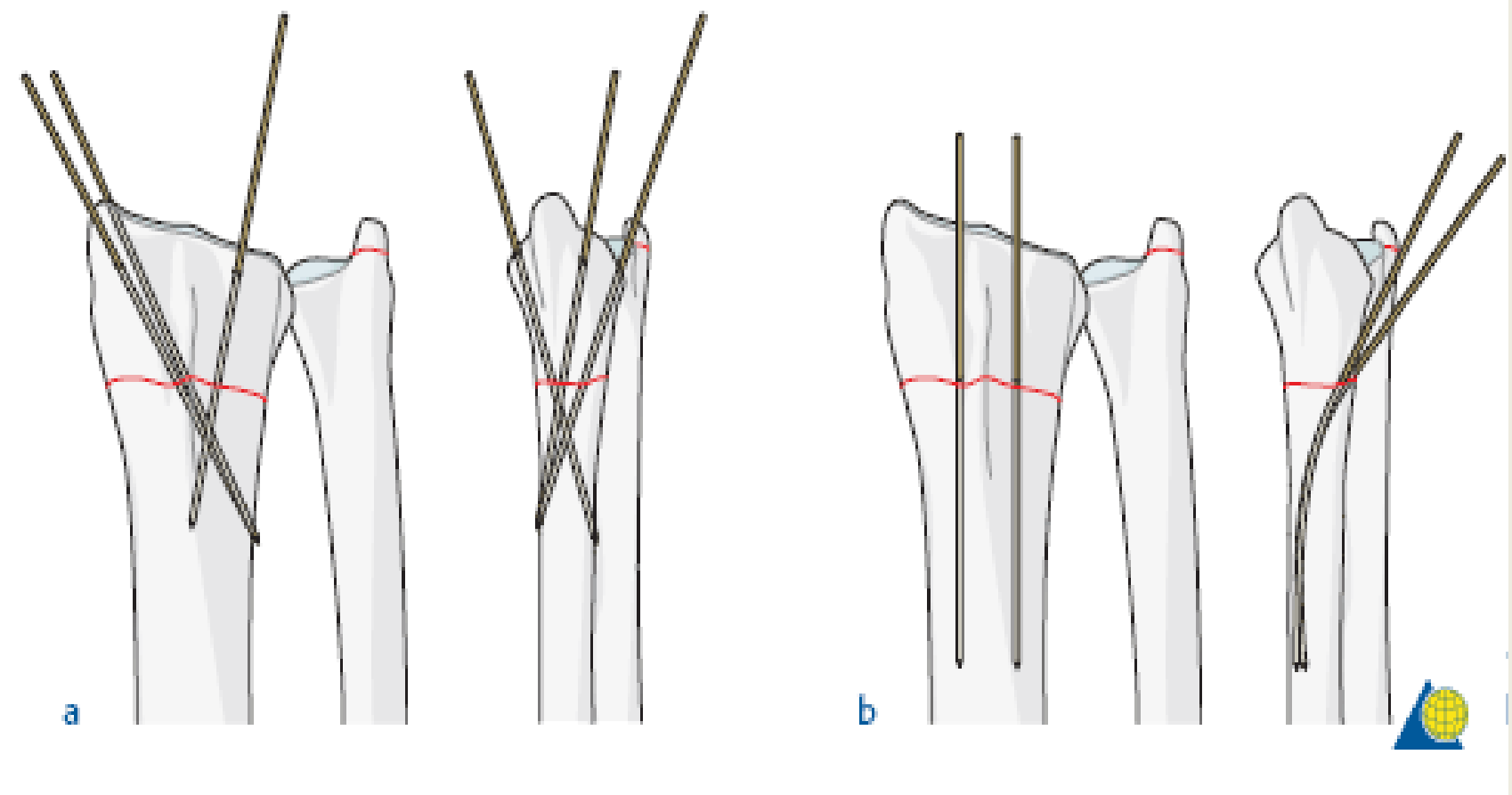

Percutaneous K wires

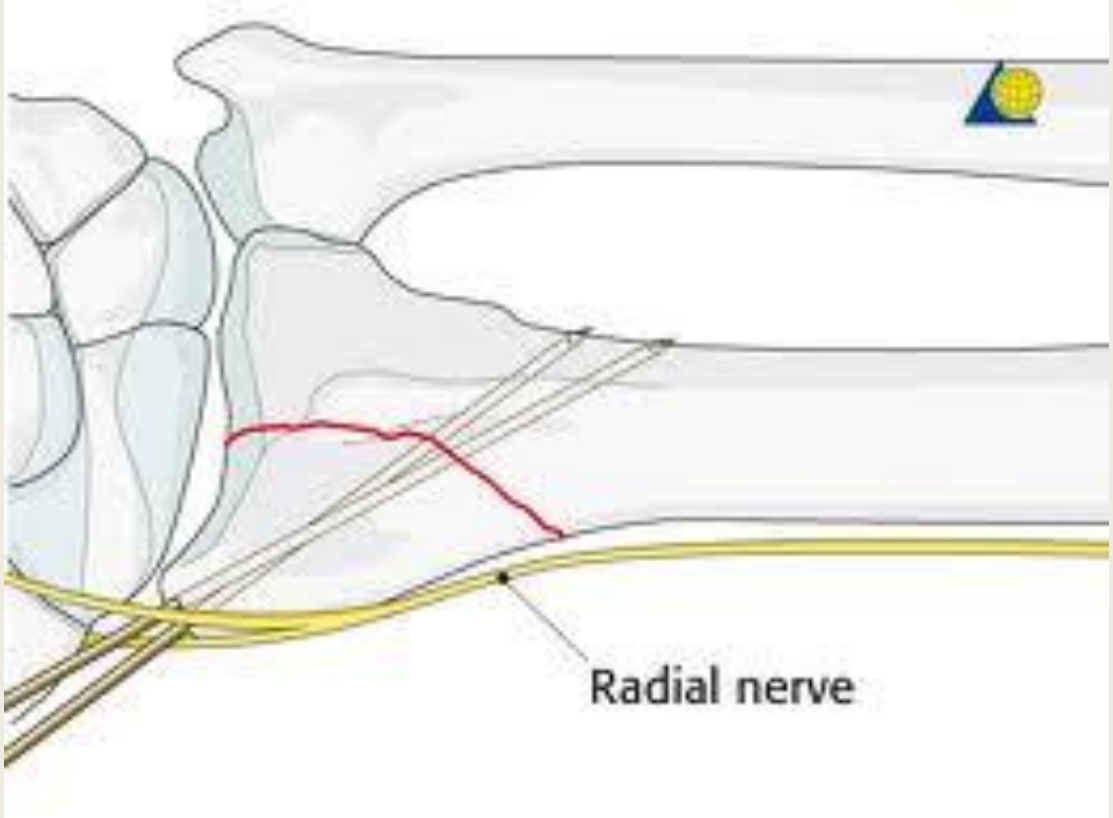

Volar Plate Fixation – A Revolution?

Volar Plate in use

Volar Plating

- Tricks and tips
- Careful dissection, avoid need for distal screws
- Percutaneous clamps and fragment specific locking screws

Die-Punch Lesion

Elevate die-punch, bone graft and minimal percutaneous fixation under image intensifier control

External Fixation

External Fixator

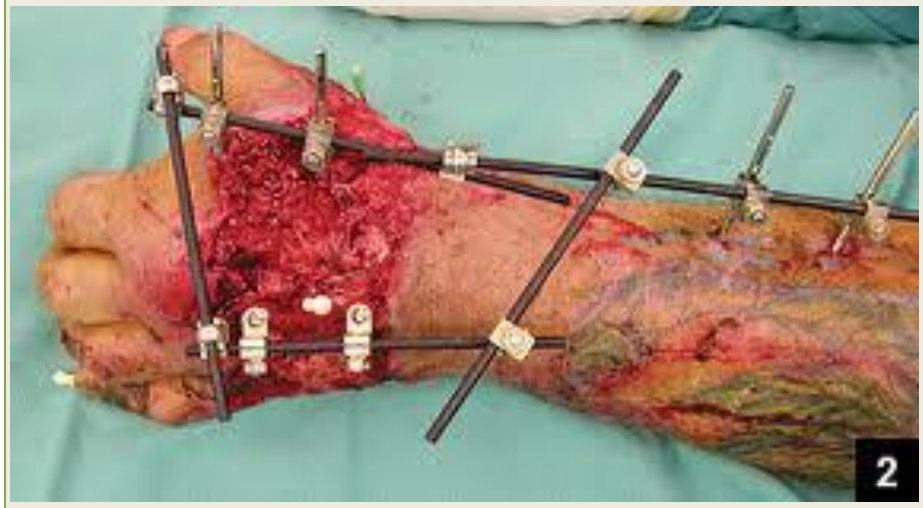

- can be useful with severe comminution; ligamentotaxis with limited internal fixation;
- Occasionally appropriate

Post Operative Care

- **Conservative treatment** - 6 week period to ensure bone healing.
- Removal of K wires and 1-2 additional weeks of support in removal plastic splint generally advised. A stable fracture may be treated with a combination of casting and splinting throughout.

Post Operative Care 2

- **Internal Fixation -** patient who has undergone internal fixation surgery for a distal radius fracture may begin gentle wrist range of motion within 1-2 weeks of surgery, after which time a removable splint used to support the hand.
- The plate left in place or removed at a later date.

Post Operative Care 3

- **External Fixation**
- The external frame and pins are usually removed sequentially, beginning 3-6 weeks after surgery, followed by a few additional weeks of removable splint wear.

Possible Complications

- **Swelling**
- **Bleeding**
- **Neurovascular injury**
- **Compartment syndrome**

Possible Complications 2

- DRUJ problems – what to do
- Non union
- Metal work penetrating the joint – OA/Fusion plate

Volar Plate Potential Complications

Subchondral Metalwork affecting joint

Wrist Fusion Might be Required

Ulnar Locking Plate and DRUJ Problems

As a last resort, wrist replacement

Synthes plate for wrist fusion

Designing a plate and screws system to follow AO's basic fracture principles

Screws

- 2.7 mm and 3.5 mm locking screws
- 2.4/2.7/3.5 cortex screws
- Self-tapping for easy insertion
- Self-retaining Stardrive recess provides improved torque transmission and increased resistance to stripping
- Locking screws with threaded head are used in Combi holes to create a fixed-angle construct, particularly advantageous to osteopenic bone

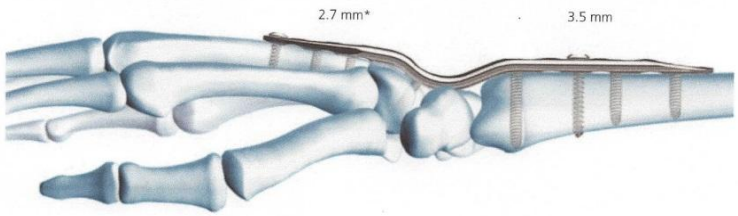

* Distal holes accept 2.4 mm cortex screws also

The End